

12**AUTOPSY REPORT**

No. 2008-09019

PARDO, BRUCE J.

Page 2**DATE OF INJURY:**

December 25, 2008

CIRCUMSTANCES:

Please see the Investigators Report for details related to the Examiner at the time of the autopsy.

DESCRIPTION OF GUNSHOT WOUND**GUNSHOT WOUND #1, a gunshot wound to the head.**

Entrance wound: The entrance wound is located inside the mouth, roughly along the midline, at the soft palate. This wound measures roughly 2-inches. There is a tear along the midline of the hard palate with separation of the palatine and maxilla bones with the fracture line extending to an area 1/2-inch above the space between the left first and second upper incisors. Sooting is present along the edges of the wound. There is no evidence of trauma to the tongue; however, some drying artifact may obscure any markings. There is no evidence of trauma to the buccal mucosa, oral mucosa, or the lips. No stippling is present. There is a 1/4-inch tear to the gingival mucosa on both sides of the left lower incisor, and this incisor is loose.

Exit wound: The exit wound is located at the top of the head, along the midline, and 1/2-inch in front of a vertical plane that passes through both ear canals. This wound is an irregular 1-1/2-inch "X" shaped, stellate like wound that reapproximates well.

Projectile recovered: A projectile is not recovered. Tiny fragments are discerned on x-rays; however, these fragments are not recovered as they are not of evidentiary value.

12**AUTOPSY REPORT**

No. 2008-09019

PARDO, BRUCE J.

Page 3

Direction: The direction of the wound is upward.

Path: This gunshot wound traverses a path with adjacent hemorrhage and loss of substance through the oral mucosa and soft palate, upward through the skull creating a 1-1/2-inch defect in front of the sella turcica involving the upper and middle cranial fossae with multiple adjacent fracture lines. The dura is perforated. The brain is perforated with a path upward, in front of the brainstem and midbrain, through the basal ganglia and frontal and parietal lobes of the cerebral cortex. The projectile perforates the dura and creates an externally beveled defect at the top of the skull with multiple radiating fracture lines. The internal table measures 3/4 x 3/4 inch. The external table measures 1-1/2 x 1 inch. Multiple areas of subgaleal hemorrhage are present. The projectile exits through the galea and scalp.

Opinion: This gunshot wound is a fatal wound inflicted during life. The gunshot wound entrance is a contact wound. The wound is self-inflicted.

EVIDENCE OF OTHER PERIMORTEM AND POSTMORTEM LESIONS:

There are two yellow/orange perimortem lesions below the left eye, measuring 1/8-inch and 1/4-inch.

There is a 2-1/2-inch burn on the posterior right neck with multiple other adjacent areas of denuded skin over a 1-inch area.

There are multiple areas of burns, punctate lesions, and skin slippage over about 40 percent of the left forearm, hand, and fingers. The majority of the lesions appear to be second to third degree thermal burns. There smaller similar lesions, up to 1-inch long, to the back and front of the right hand as well as the thumb and 2nd thru 4th fingers.

12**AUTOPSY REPORT**

No. 2008-09019

PARDO, BRUCE J.

Page 4

There is a 1-inch faint bruise to the right forearm near the antecubital fossa. There is a 1/4-inch perimortem lesion to the right upper thigh. There is a 1-inch abrasion with drying artifact on the upper right lower leg. There is a 1/4 x 1/8-inch punctate abrasion to the right lower leg. There is a 1-1/2 x 1 inch abrasion with a large amount of dried blood and with several small adjacent punctate lesions on the lower left thigh.

DESCRIPTION OF OTHER EXTERNAL MARKINGS:

No tattoos are present.

There is a 1/8-inch skin tag on the lateral right chest. There are multiple small faint hyperpigmented lesions on both shoulders, the upper chest, and both lower legs near the ankles. There are multiple tiny hypopigmented scars on the face.

EVIDENCE OF THERAPEUTIC INTERVENTION:

There is no evidence of therapeutic interventions.

There is evidence of older surgery: there is a 12-inch, well healed scar on the left lower leg, and surgical hardware is present on x-rays of the left lower leg.

ORGAN PROCUREMENT:

There is no evidence of postmortem intervention for organ or tissue procurement.

12**AUTOPSY REPORT**

No. 2008-09019

PARDO, BRUCE J.

Page 5**CLOTHING:**

The body is examined unclothed. At the time of the autopsy, no clothing was available for examination.

EXTERNAL EXAMINATION:

The above findings of injuries and interventions will not necessarily be repeated in the remainder of this report, and for clarity descriptions such as normal, intact, and unremarkable, when used, will refer to normal except for the above findings.

The body is identified by toe tags and an ankle bracelet and is that of an unembalmed, refrigerated adult Caucasian male who appears about the reported age of 45 years. The body reportedly weighs 258 pounds, measures 73 inches, and is mildly obese. Rigor mortis is moderately present with some alteration of the rigor of the muscles of the upper extremities. Livor mortis is mildly present, posterior, dependent, and fixed.

The head is normocephalic. The head is partially covered by short, brown/gray straight hair, about 1/2-inch long. Some frontal male pattern balding is present. A mustache is absent. A beard is absent. The remainder of the body hair is distributed normally in a male adult pattern. Examination of the eyes reveals irides that appear to be blue in color and sclerae that are clear. Some tache noir artifact is present. There are no petechial hemorrhages of the conjunctivae of the eyelids or the sclerae. The oronasal passages are unobstructed. Upper and lower teeth are present, in fair condition. Dentures are not present. The neck is unremarkable. There is no chest deformity. There is no increased anterior-posterior diameter. The abdomen is slightly round and is otherwise unremarkable. The genitalia are those of an adult male. The external genitalia are without trauma or lesions. The penis is uncircumcised. The testes are descended. The extremities show no edema, joint deformity, abnormal mobility, or needle tracks.

12**AUTOPSY REPORT**

No. 2008-09019

PARDO, BRUCE J.

Page 6**INITIAL INCISION:**

The body cavities are entered through the standard coronal incision and the standard Y-shaped incision. No foreign material is present in the mouth, upper airway, and trachea. The body tissues are normally hydrated.

NECK:

The neck organs are removed en bloc with the tongue. No other lesions are present, nor is trauma of the gingiva, lips or oral mucosa demonstrated. There is no edema of the larynx. The larynx is intact and without fractures. No hemorrhage is present in the adjacent throat organs, investing fascia, thyroid or visceral fascia. There are no prevertebral fascia hemorrhages. The tongue when sectioned reveals no evidence of trauma.

CHEST AND ABDOMINAL CAVITIES:

Both pleural cavities are free of adhesions and fluid. No tension pneumothorax is demonstrated. The lungs are well expanded. Soft tissues of the thoracic and abdominal walls are well preserved. The subcutaneous fat of the abdominal wall is 4.0 cm. The breasts are examined in the usual manner, and are unremarkable. The organs of the abdominal cavity have a normal arrangement, and none are absent. The peritoneal cavity has no evidence of peritonitis. There are no adhesions. There is no ascites.

12**AUTOPSY REPORT**

No. 2008-09019

PARDO, BRUCE J.

Page 7**SYSTEMIC AND ORGAN REVIEW****MUSCULOSKELETAL SYSTEM:**

In the areas of dissection, no abnormalities of the bony framework or muscles are present. The muscles are well developed.

CARDIOVASCULAR SYSTEM:

The aorta is elastic and of even caliber throughout, with vessels distributed normally from it. The aorta is free of atherosclerosis. There is no tortuosity or widening of the thoracic segment. There is no dilation of the lower abdominal segment. The major branches of the aorta show no abnormality.

The pericardial sac is smooth. The sac contains a sparse amount of clear fluid. The heart weighs 470 grams. It has an enlarged configuration. The right ventricle is 0.3 cm thick. The left ventricle is 1.2 cm thick. The septal wall is 1.2 cm thick. The chambers are normally developed and are without mural thrombosis. The valves are thin, leafy and competent. The valve circumferences in cm are mitral 11.0, aortic 7.0, tricuspid 14.5, and pulmonic 7.5. There is no endocardial discoloration. There are no lesions of the myocardium. There is no abnormality of the apices of the papillary musculature. The great vessels enter and leave in a normal fashion. The ductus arteriosus is obliterated. The coronary ostia are widely patent. The left coronary artery is the dominant vessel. There is a balanced and normal pattern of coronary artery distribution. There are no coronary atherosclerotic markings of the major coronary arteries. No focal endocardial, valvular or myocardial lesions are seen. The heart and large blood vessels contain fluid blood.

12**AUTOPSY REPORT**

No. 2008-09019

PARDO, BRUCE J.

Page 8**RESPIRATORY SYSTEM:**

Scant secretions are found in the upper respiratory airway and in the lower bronchial passages. The mucosa is intact and pale. Both lungs are mildly congested with a moderate amount of increased dependent congestion, and a moderate amount of anthracotic markings. The left lung weighs 680 grams. The right lung weighs 640 grams. The visceral pleurae are smooth and intact. Cross-sections of the parenchyma are unremarkable. No blood aspiration pattern is noted. The pulmonary vasculature is without thromboembolism.

GASTROINTESTINAL SYSTEM:

The esophagus is intact throughout. The stomach is not distended. It contains about 120 grams of partially digested food. The mucosa is unremarkable. Portions of tablets and capsules cannot be discerned in the stomach. The external and in-situ appearances of the small intestine and colon are unremarkable. The small intestine and colon are opened along the anti-mesenteric border. An unremarkable mucosal surface and contents are noted. The appendix is unremarkable. The pancreas occupies a normal position. There is a marked amount of early autolysis, some fatty infiltration present, and no necrosis present. The parenchyma is lobular and firm. The pancreatic ducts are not ectatic, and there is no parenchymal calcification.

HEPATOBIILIARY SYSTEM:

The liver weighs 2080 grams, is of average size, and is red-yellow. The capsule is intact and thin. The consistency of the parenchyma is greasy. The cut surface shows marked fatty change. There is a normal lobular arrangement. The gallbladder is not identified. There is no obstruction or dilation of the

12**AUTOPSY REPORT**

No. 2008-09019

PARDO, BRUCE J.

Page 9

extra-hepatic ducts except for a small area of dilatation near the liver that contains a small 1/8-inch irregular green stone. The periportal lymph nodes are not enlarged.

URINARY SYSTEM:

The left kidney weighs 160 grams. The right kidney weighs 150 grams. They are normally situated, and the capsule strip easily revealing a surface that is smooth and mildly congested. The corticomedullary demarcation is not obscured. Mild congestion is present. The bivalved surfaces are unremarkable. The pyramids are not remarkable. The peripelvic fat is not increased. The ureters are without dilation or obstruction and pursue their normal course. The urinary bladder is unremarkable. It contains about 200 ml of yellow/clear urine.

GENITAL SYSTEM:

The prostate is mildly enlarged, not nodular, and unremarkable. Both testes are in the scrotum, string well, are unremarkable, and are without trauma.

HEMOLYMPHATIC SYSTEM:

The spleen weighs 250 grams and is of average size. The capsule is thin, wrinkled, and intact. The parenchyma is brick red and soft. There is no increased follicular pattern. Lymph nodes throughout the body are small and inconspicuous. The bone is not remarkable. The bone marrow of the ribs is red, moist and unremarkable.

12**AUTOPSY REPORT**

No. 2008-09019

PARDO, BRUCE J.

Page 10**ENDOCRINE SYSTEM:**

The thyroid is unremarkable. The parathyroid glands are not identified. The adrenals are unremarkable. The thymus consists of unremarkable firm pale tissue with some fatty tissue. The pituitary gland is of normal size and is unremarkable.

SPECIAL SENSES:

The eyes are not dissected. The middle and inner ear are not dissected.

HEAD AND CENTRAL NERVOUS SYSTEM:

The brain weighs 1480 grams. The galea, skull, dura, cerebral cortices, leptomeninges, ventricles, basal ganglia, diencephalon, midbrain, pons, cerebellum, brainstem, cranial nerves, and cranial vasculature are anatomic and unremarkable except for the areas of injury noted above.

SPINAL CORD:

The spinal cord is not dissected or examined except for that portion visible at the base of the skull which is unremarkable.

NEUROPATHOLOGY:

A neuropathology consultation is not requested.

12**AUTOPSY REPORT**

No. 2008-09019

PARDO, BRUCE J.

Page 12**WITNESSES:**


Detectives Regan and Robinson, Covina Police Department, attended the autopsy.

DIAGRAMS USED:

Diagrams and worksheet, Forms 16, 20, 20-G, 21, 22, 28, and 34 are used during the course of the autopsy. These diagrams are not intended to be facsimiles.

OPINION:


The decedent died of a gunshot wound to the head. The manner of death is suicide.



DAVID B. WHITEMAN, M.D.
DEPUTY MEDICAL EXAMINER

03/26/2009

DATE

DBW:dbw:pc
T-12/29/2008 @ 1753


15

AUTOPSY CLASS: A B C Examination Only D

Date 12/29/2008 Time 1330 Dr. William

FINAL ON 12/29/2008 By William print

print

APPROXIMATE INTERVAL BETWEEN ONSET AND DEATH

DEATH WAS CAUSED BY: (Enter only one cause per line for A, B, C, and D)

IMMEDIATE CAUSE

(A) Gunsight Wound to the Head ← Ruff

DUE TO, OR AS A CONSEQUENCE OF

(B) DUE TO, OR AS A CONSEQUENCE OF

(C) DUE TO, OR AS A CONSEQUENCE OF

(D) DUE TO, OR AS A CONSEQUENCE OF

Other conditions contributing but not related to the immediate cause of death:

- NATURAL SUICIDE HOMICIDE
- ACCIDENT COULD NOT BE DETERMINED

If other than natural causes HOW DID INJURY OCCUR? Self-inflicted gunshot wound

WAS OPERATION PERFORMED FOR ANY CONDITION STATED ABOVE: YES NO

TYPE SURGERY _____ DATE _____

ORGAN PROCUREMENT TECHNICIAN Clara

WITNESSES TO AUTOPSY EVIDENCE RECOVERED AT AUTOPSY

For dette hrs
Clara
15 yls Clara

Item Description: _____

Resident

DME

Shm #6

PRIOR EXAMINATION REVIEW BY DME

- BODY TAG CLOTHING
- X-RAY (No 3) FLUORO
- SPECIAL MED. RECORDS
- PROCESSING TAG
- AT SCENE PHOTOS (No _____)

TYPING BLOOD TAKEN BY RL

SOURCE H&K

TOXICOLOGY

- NO BLOOD
- Embalmed
- >24 hr in hospital
- Decomposed
- Other _____ Reason

SPECIMENS

- Collected by RL
- HEART BLOOD STOMACH CONT.
- FEMORAL BLOOD BRAIN
- _____ BLOOD SPLEEN
- _____ BLOOD KIDNEY
- BILE VITREOUS
- LIVER _____
- URINE _____

STORAGE JARS

- Regular (No three) Oversize (No _____)
- Histopath Cut: Autopsy Lab

NO TOXICOLOGY REQUESTED

TOXICOLOGICAL ANALYSES ORDERED

- SCREEN: C H T S
- ALCOHOL ONLY
- CARBON MONOXIDE
- NEOGEN SCREEN
- OTHER (specify drug and tissue)

REQUESTED MATERIAL ON PENDING CASES

- Police Report Med History
- Tox Histo
- Microbiology Investigations
- Radiology Cons. Eye Path. Cons
- Consult on _____
- Brain Submitted
- Neuro Consult DME to Cut
- Criminalistics
- GSR Sexual Assault Other

16

EXTERNAL EXAM

Sex *Male*
 Race *Caucasian*
 Age *45*
 Height *73*
 Weight *250*
 Hair *1/2 grey & straight*
 Eyes *blue*
 Sclerae
 Teeth
 Mouth
 Tongue
 Nose
 Chest
 Breasts
 Abdomen
 Scar
 Genitals
 Edema
 Skin
 Decubitus

HEART Wt.

470
 Pericardium *spare* RV *0.3*
 Hypertrophy Septum *1.2*
 Dilation LV *1.2*
 Muscle Septum
 Valves
 Coronaries

AGRTA

VESSELS

LUNGS Wt.

R *670*
 L *650*
 Adhesions
 Fluid
 Atelectasis
 Oedema
 Congestion
 Consolidation
 Bronchi
 Nodes

PHARYNX

TRACHEA

THYROID

THYMUS

LARYNX

HYOID

ABDOMINAL WALL FAT

PERITONEUM

Fluid *small*
 Adhesions

LIVER Wt.

2050
 Capsule *fatty*
 Lobules *liver*
 Fibros
 G B
 Calculus
 Bile ducts

SPLEEN Wt.

250
 Color
 Consistency
 Capsule
 Malpiment

PANCREAS

ADRENALS

KIDNEYS Wt.

R *150*
 L *160*
 Capsule
 Cortex
 Vessels
 Pelvis
 Ureters

BLADDER

GENITALIA

Prostate
 Testes
 Uterus
 Tubes
 Ovaries

OESOPHAGUS

STOMACH

Contents

DUOD. & SM. INT.

APPENDIX

LARGE INT.

ABDOM. NODES

SKELETON

Spine
 Marrow
 Rib Cage
 Long bones
 Pelvis

SCALP

CALVARIUM

BRAIN Wt.

1250
 Dura
 Fluid
 Ventricles
 Vessels
 Middle ears
 Other

PITUITARY

SPINAL CORD

TOXICOLOGY SPECIMENS

*H-Blood F-Blood
 3077
 urine V. H. es Steady*

SECTIONS FOR HISTOPATHOLOGY

MICROBIOLOGY

*DIAGRAMS 20 208, 21
 X-RAYS 3 22, 28, 34*

OTHER PROCEDURES

GROSS IMPRESSIONS

Cause to find

Date

Time

Deputy Medical Examiner



Department of Coroner, County of Los Angeles
FORENSIC SCIENCE LABORATORIES
 Laboratory Analysis Summary Report



Wednesday, January 21, 2009

To: Dr. Whiteman
 Deputy Medical Examiner

PendingTox

Subject: Coroner Case Number 2008-09019 PARDO, BRUCE JEFFREY

The following results have been technically and administratively reviewed and are the opinions and interpretations of the Analyst:

<u>SPECIMEN</u>	<u>SERVICE</u>	<u>DRUG</u>	<u>LEVEL</u>	<u>UNITS</u>	<u>ANALYST</u>
Blood, Heart					
	Alcohol	Ethanol		Negative	M. Schuchardt
	Barbiturate	Barbiturates		ND	O. Pleitez
	Bases	Basic Drugs		ND	S. DeQuintana
	Cocaine	Benzoylcegonine	0.07	ug/ml	R. Budd
	Cocaine	Cocaethylene		ND	R. Budd
	Cocaine	Cocaine	< 0.03	ug/ml	R. Budd
	Fentanyl	Fentanyl		ND	O. Pleitez
	Marijuana	Carboxy-THC		ND	O. Pleitez
	Methamphetamine	Methamphetamine		ND	O. Pleitez
	Opiates	Codeine		ND	O. Pleitez
	Opiates	Morphine		ND	O. Pleitez
	Phencyclidine	Phencyclidine		ND	O. Pleitez
Urine					
	Cocaine	Benzoylcegonine	0.99	ug/ml	R. Budd
	Cocaine	Cocaethylene		ND	R. Budd
	Cocaine	Cocaine	0.66	ug/ml	R. Budd

Legend:

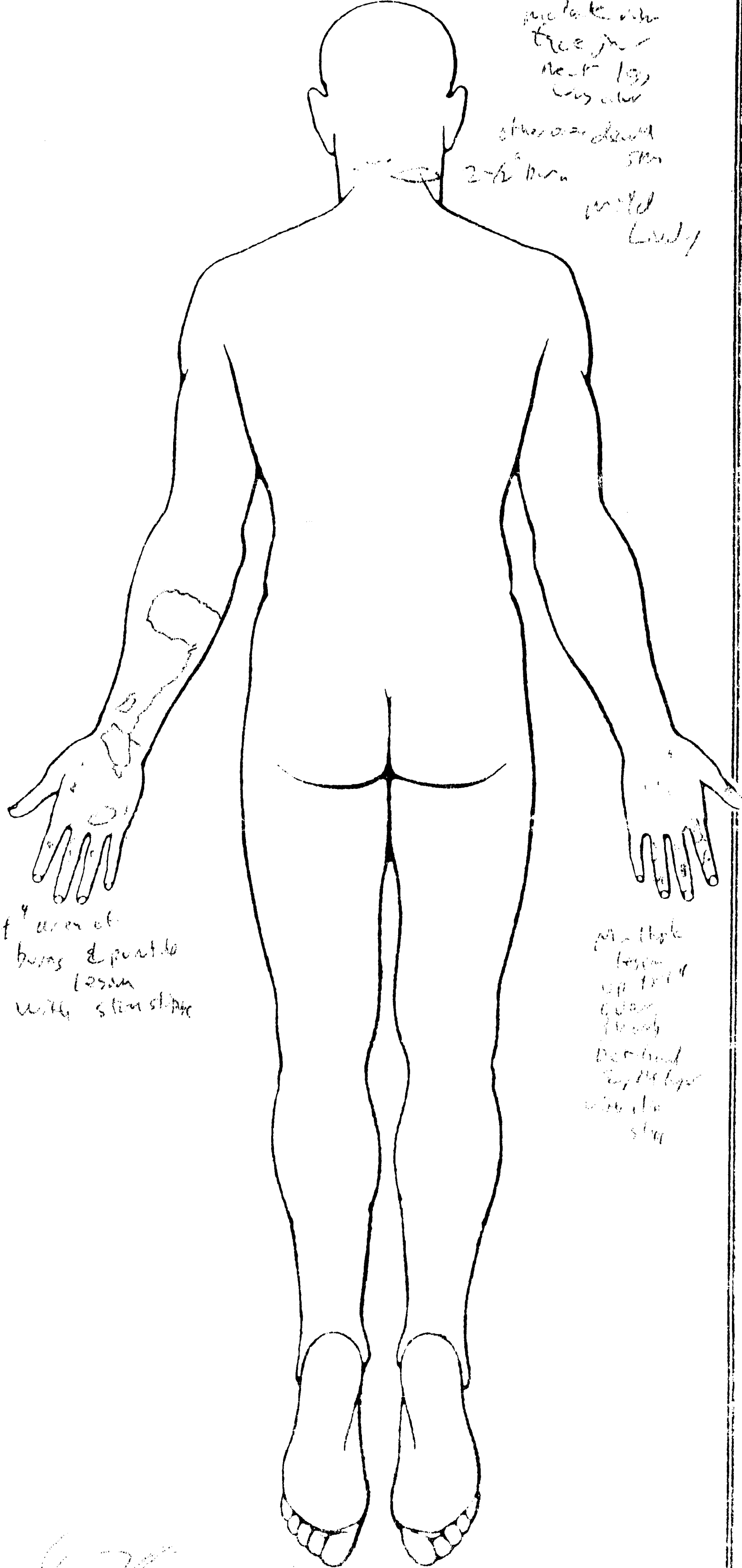
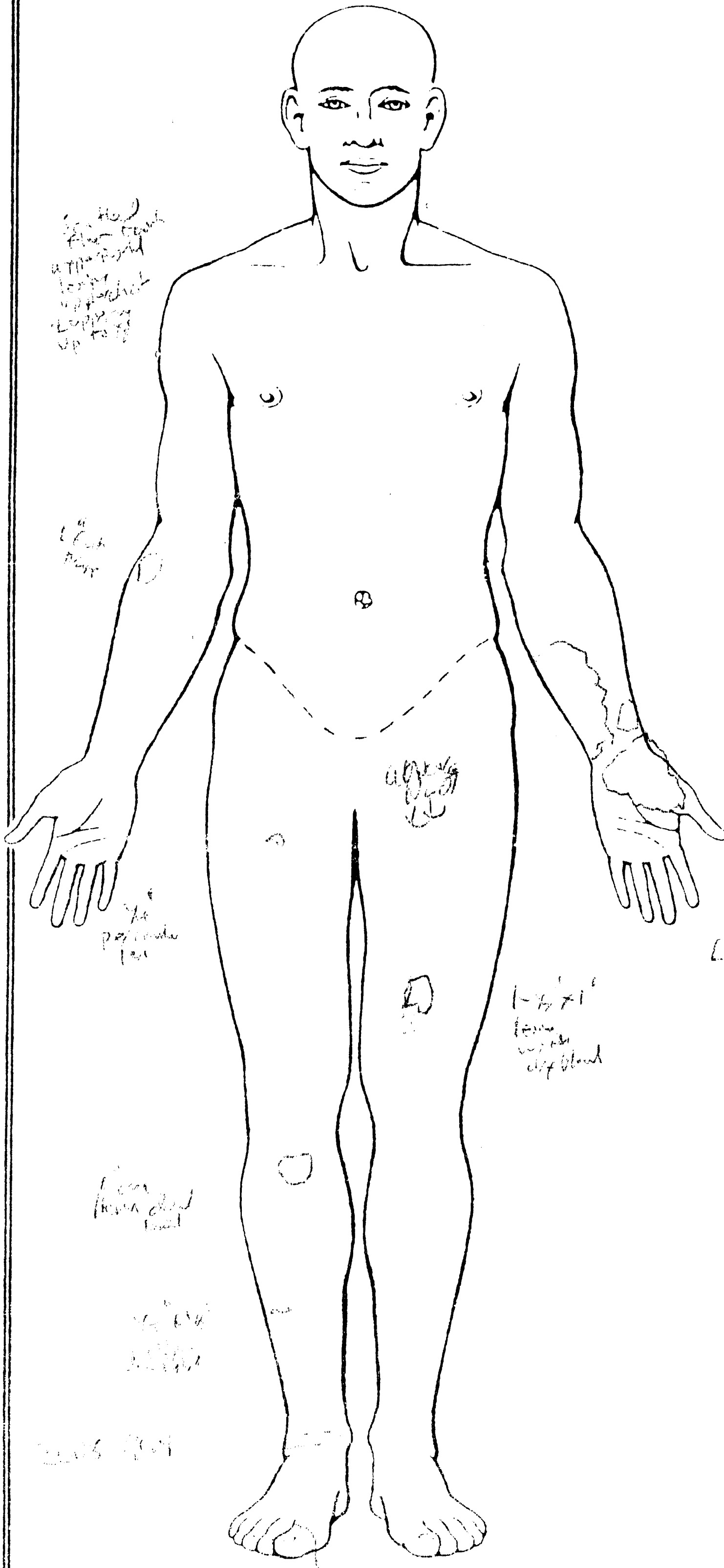
-----		QNS	Quantity Not Sufficient
% Saturation		TNP	Test Not Performed
*		Trace	
Done		ug	Micrograms
g	Grams	ug/g	Micrograms per Gram
g%	Gram Percent	ug/l	
Inc.	Inconclusive	ug/ml	Microgram per Milliliter
mEq/l	Milli equivalents		
mg	Milligrams		
mg/dl	Milligram per Deciliter		
mg/l	Milligram per Liter		
mmol/l	Millimoles per Liter		
ND	Not Detected		
Negative			
ng/gm	Nanograms per Gram		

Administratively reviewed by: *D. Anderson*
Daniel T. Anderson
 Supervising Criminalist II
 FORENSIC LABORATORIES

20

1974 Caucasian male
73" 255 lb

12/10/74
12/10/74



Head
Face
Neck
Lungs
up

Left
Hand

Right
Hand

Right
Hand

Right
Hand

Right
Hand

Right
Hand

Right
Hand

1-1/2 x 1"
Laceration
with
deep bleed

Left
arm at
humerus & possible
lesion
with skin slough

neck
free
Neck
Lungs
Other
2-1/2 hrs
wild
Lungs

Right
Hand
up
Right
Hand
Right
Hand
Right
Hand

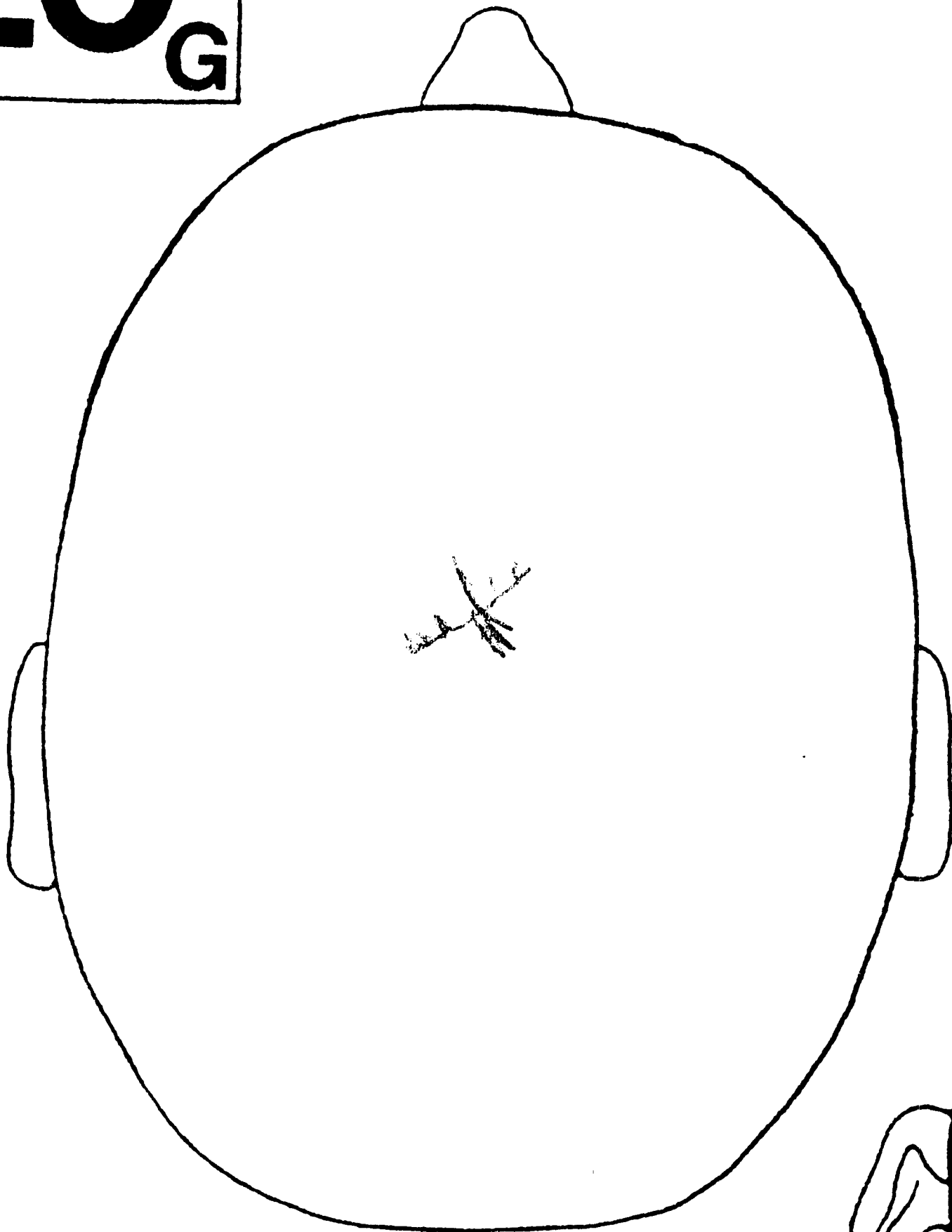
[Signature]

12/10/74

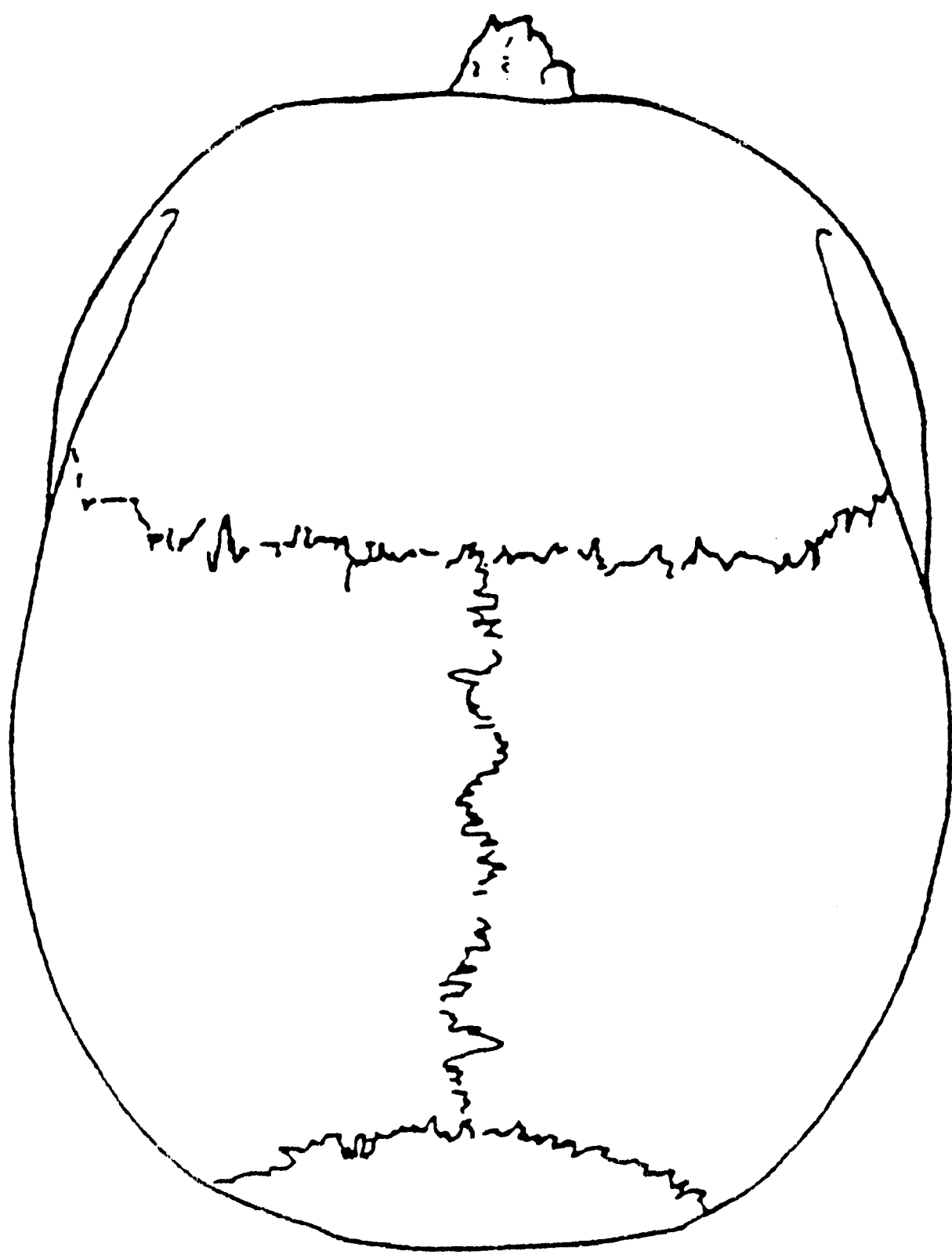
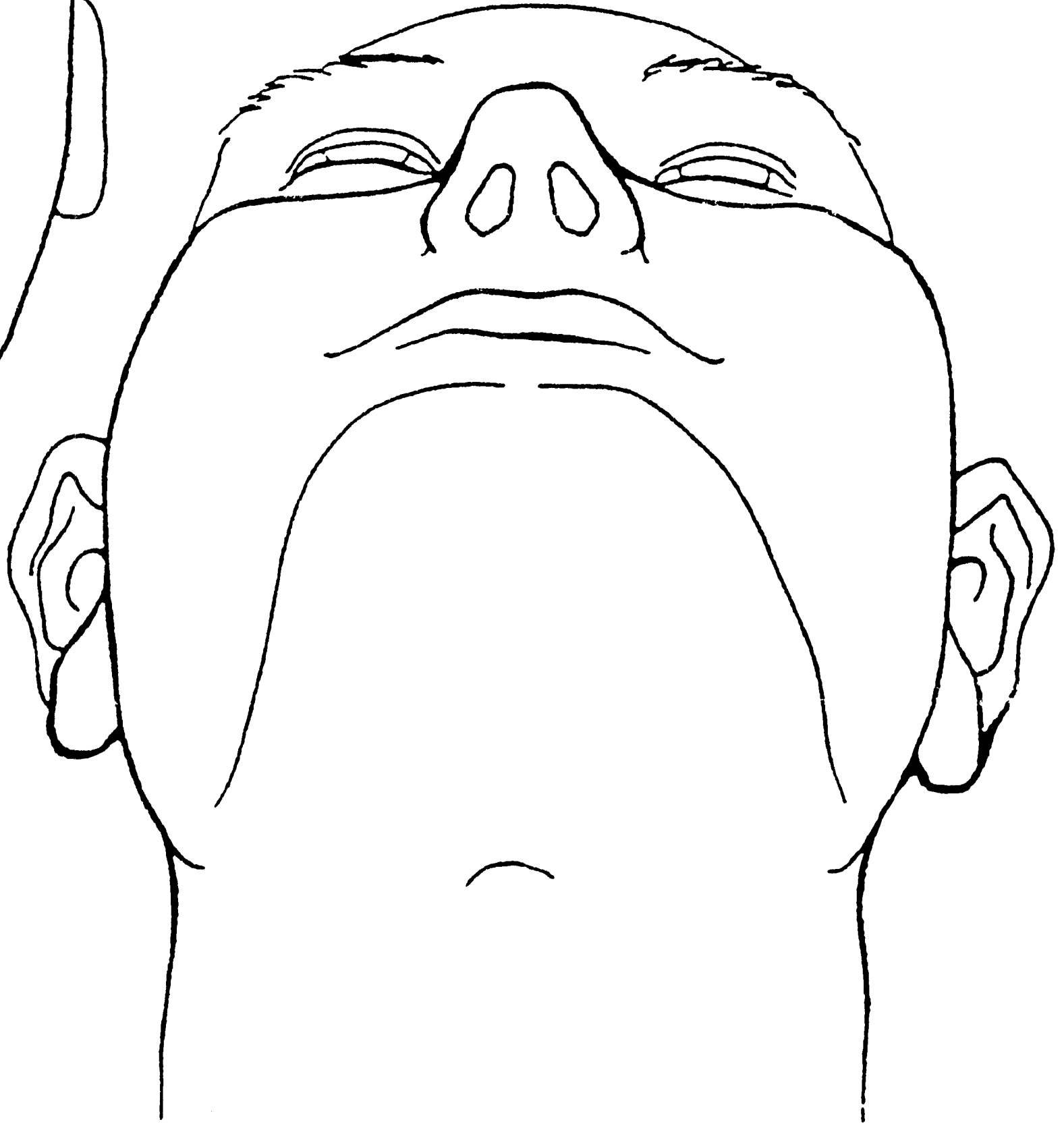Deputy Medical Examiner

M.D.

20_G



1-2 "X" marks
stellate wound
@ Top of the
to base of nose

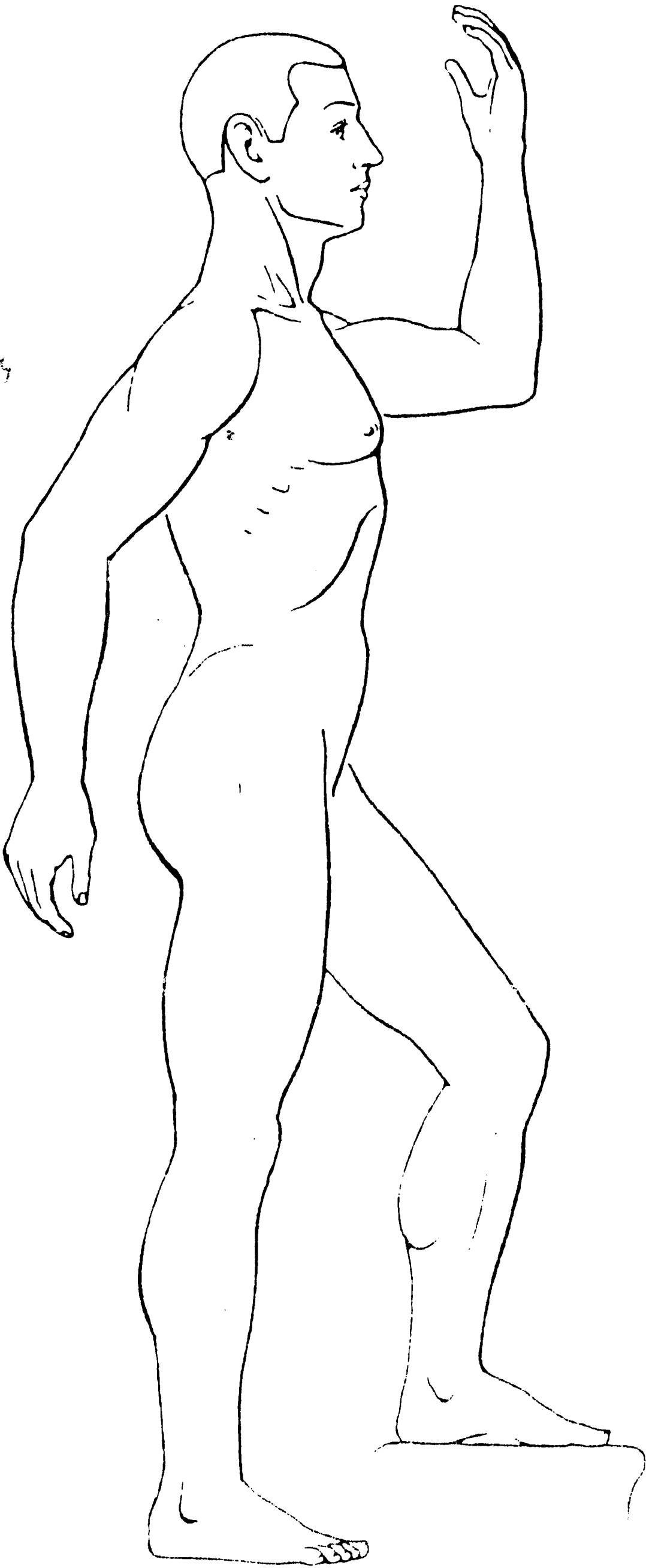


Date	12/12/04
	<i>[Signature]</i>
M.D.	
Deputy Medical Examiner.	

21

PHYSICIAN
BY APPOINTMENT

1/8" study



Rt



*12" study
500
1/8" study
02/13*

Lt

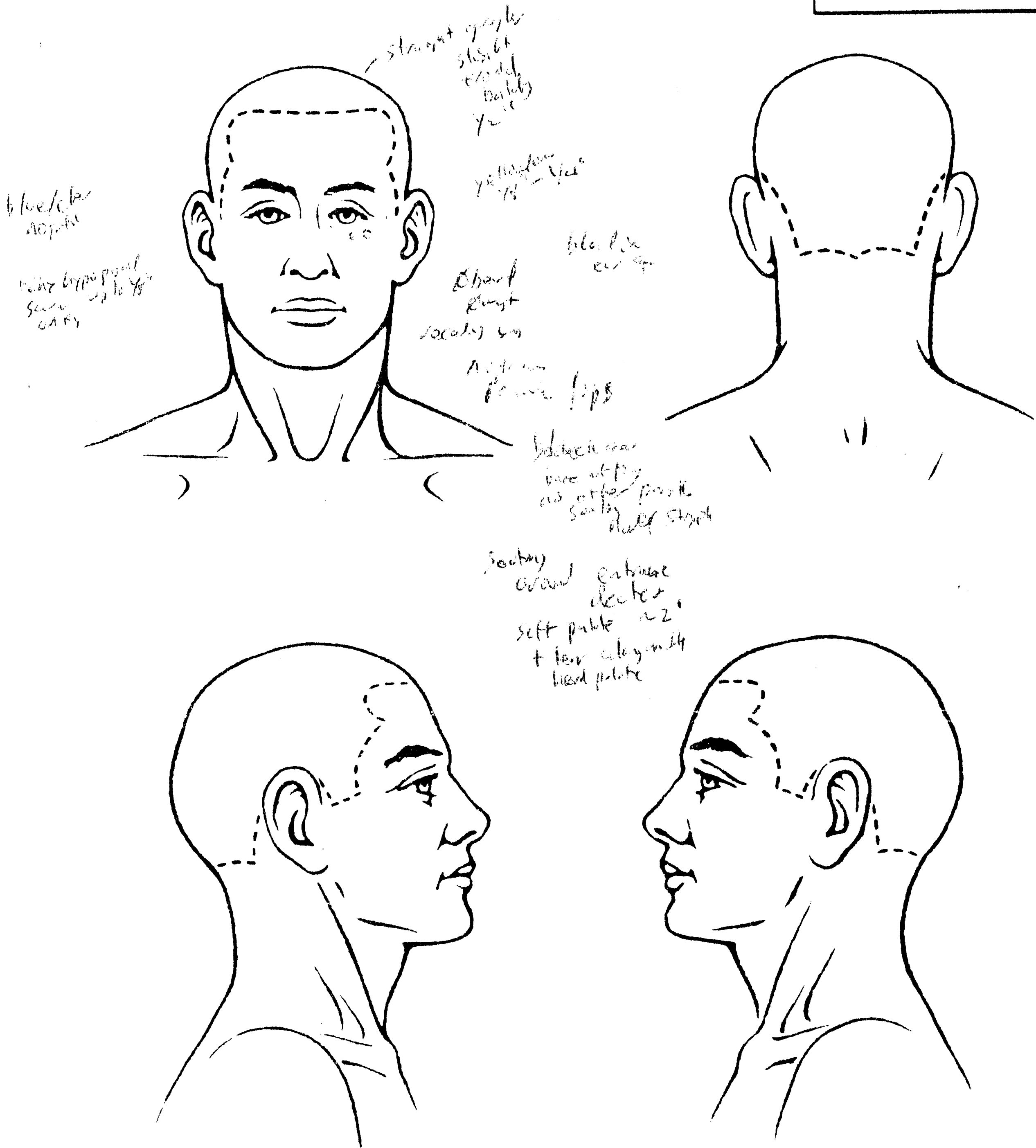
[Handwritten signature]

M.D.

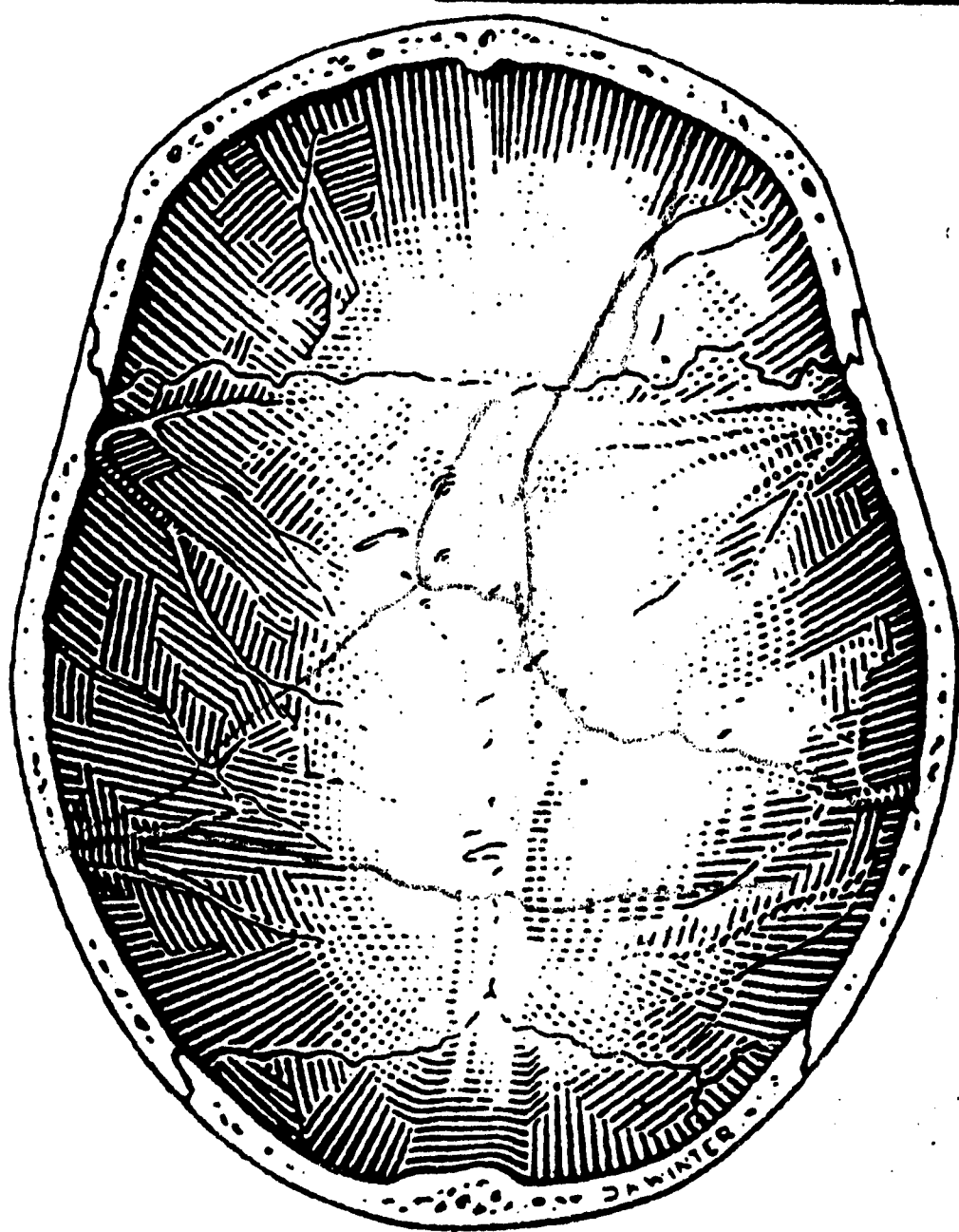
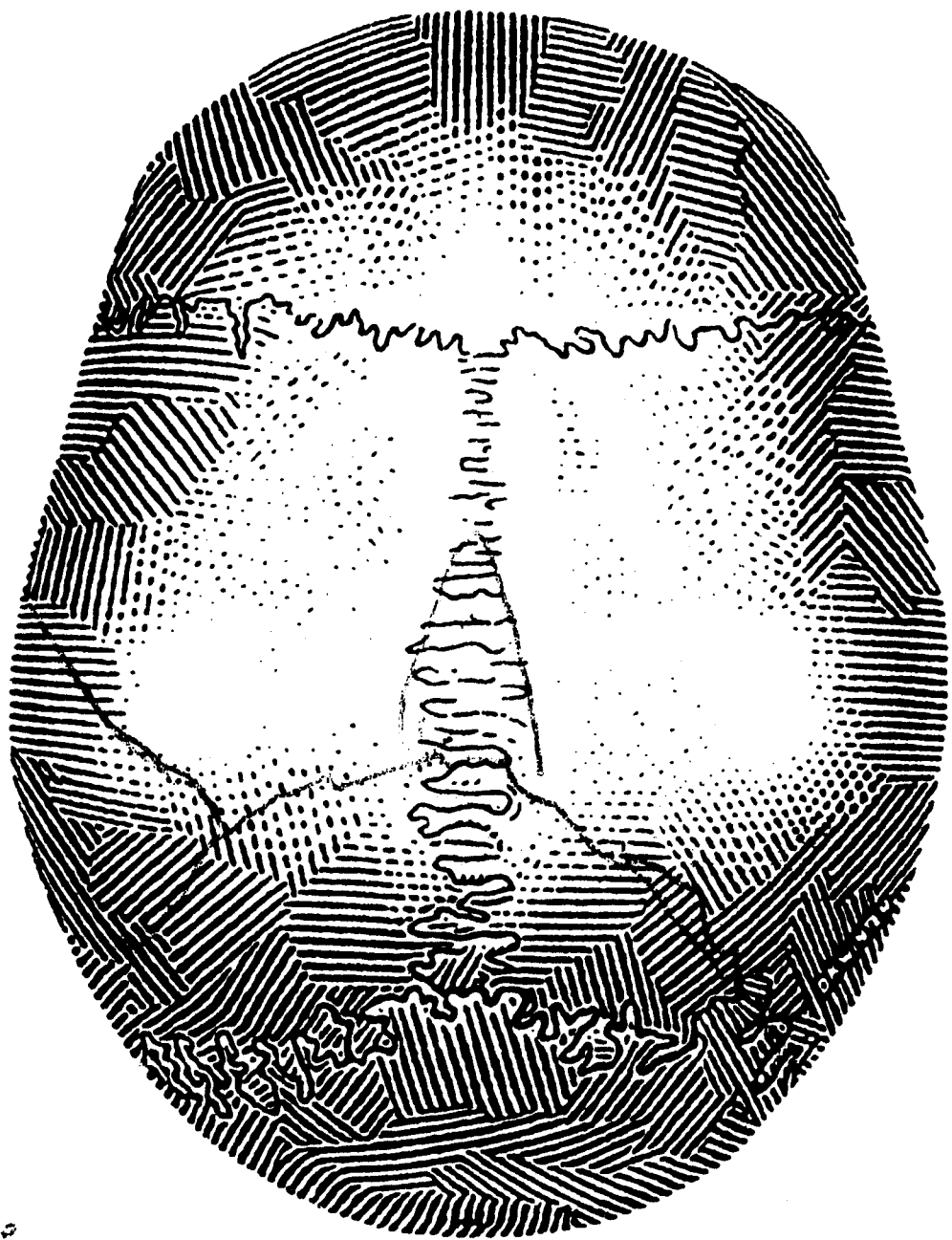
Deputy Medical Examiner

22

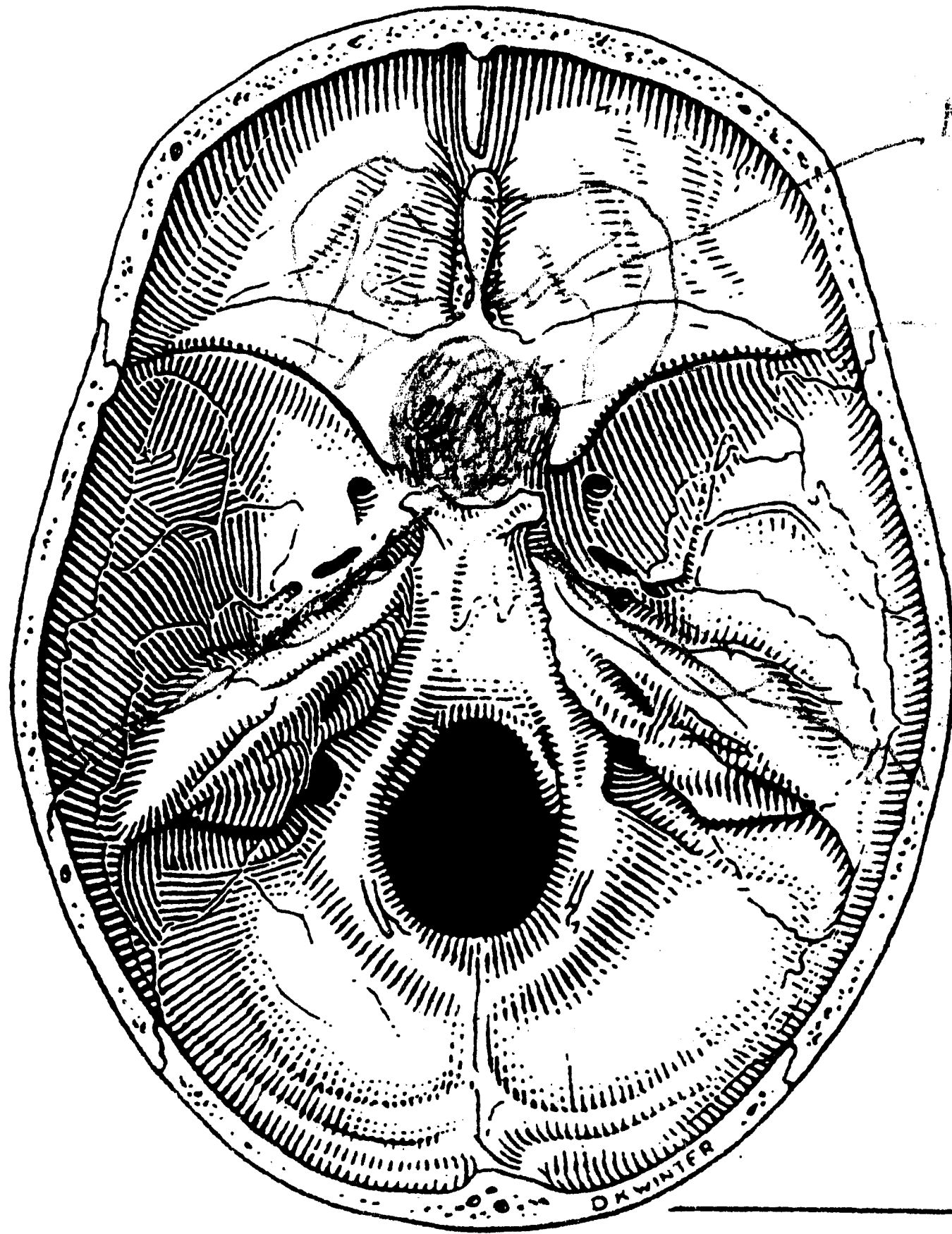
2008-09017
PAID, BRUCE JEFFREY
SM



[Signature]
Deputy Medical Examiner M.D.



*External table
Internal table
Cribriform plate*



Multiple fracture

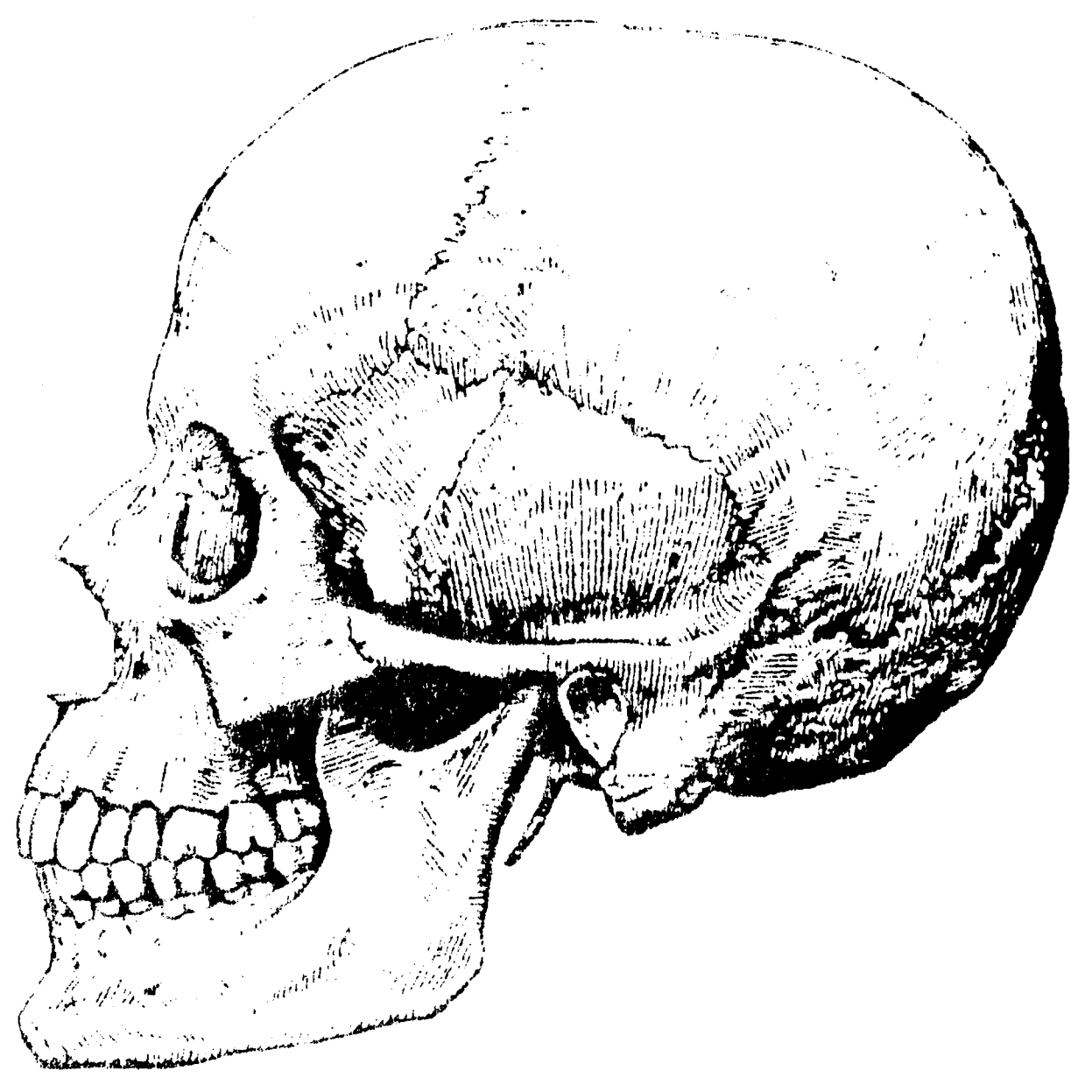
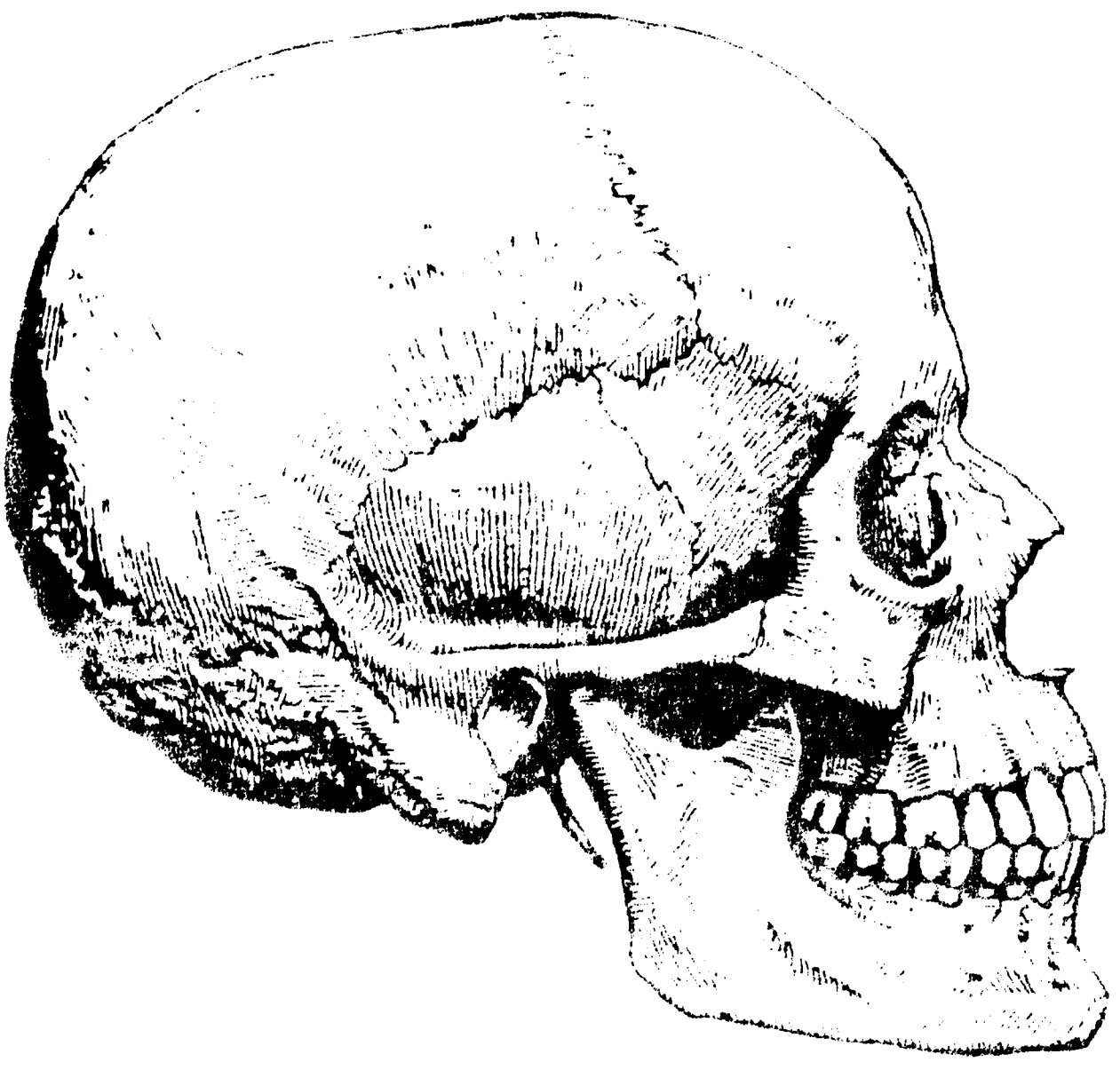
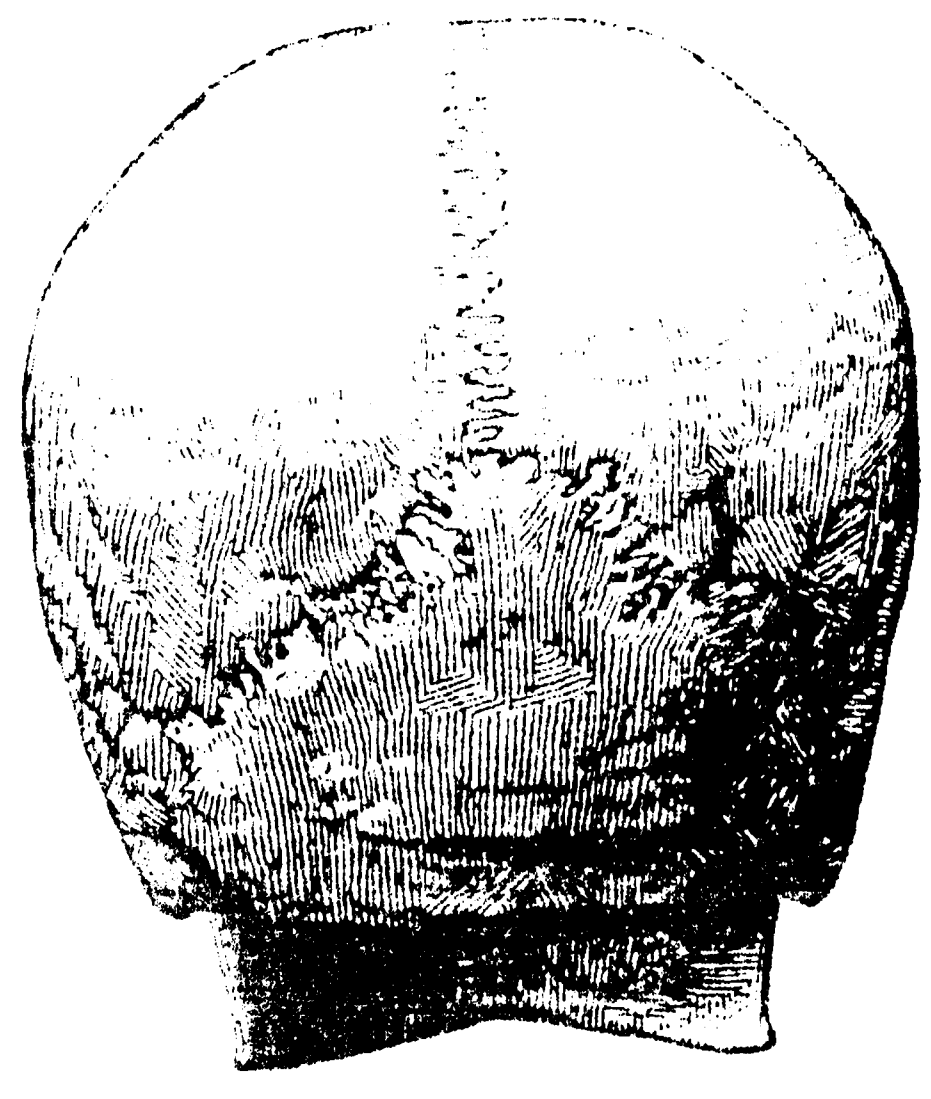
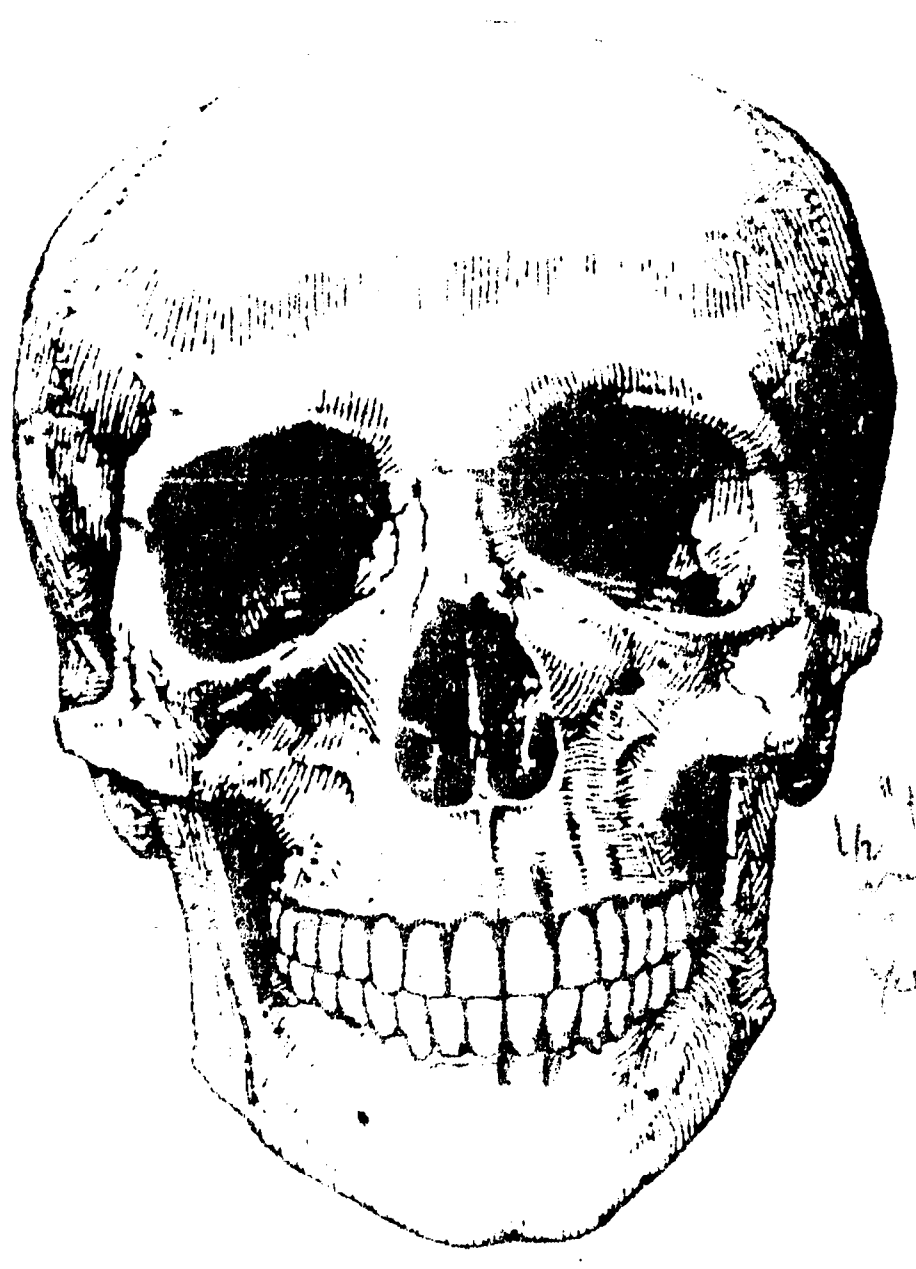defect

[Signature]

Deputy Medical Examiner

M.D.

2017-2018
FACULTY OF MEDICINE
SCHOOL OF DENTISTRY
7/11



[Signature] M.D.
Dental Medical Examiner

6

WAS ORIGINAL SCENE DISTURBED BY OTHERS? Y() N()

IF YES, NOTE CHANGES IN NARRATIVE FORM #3.

DATE 12/25/8

AMBIENT #1 55.4 °F TIME 1306

AMBIENT #2 _____ °F TIME _____

WATER _____ °F TIME _____

Pardo, Bruce
2008-09019
THERMOMETER # 07-19

LIVER TEMPERATURE #1 92.8 °F TIME 1310

LIVER TEMPERATURE #2 _____ °F TIME _____

DATE & TIME FOUND 12/25/8 0310 CST LAST KNOWN ALIVE 12/24/8 2330 CST

APPROX. AGE 45 SEX M EST. HEIGHT 75 EST. WEIGHT 250 CLOTHED? YES NO IF YES, DESCRIBE:
Black Thonon shirt, Black Boot, Black Pants, Green Boxers, Cap, Black Socks, Black Slippers

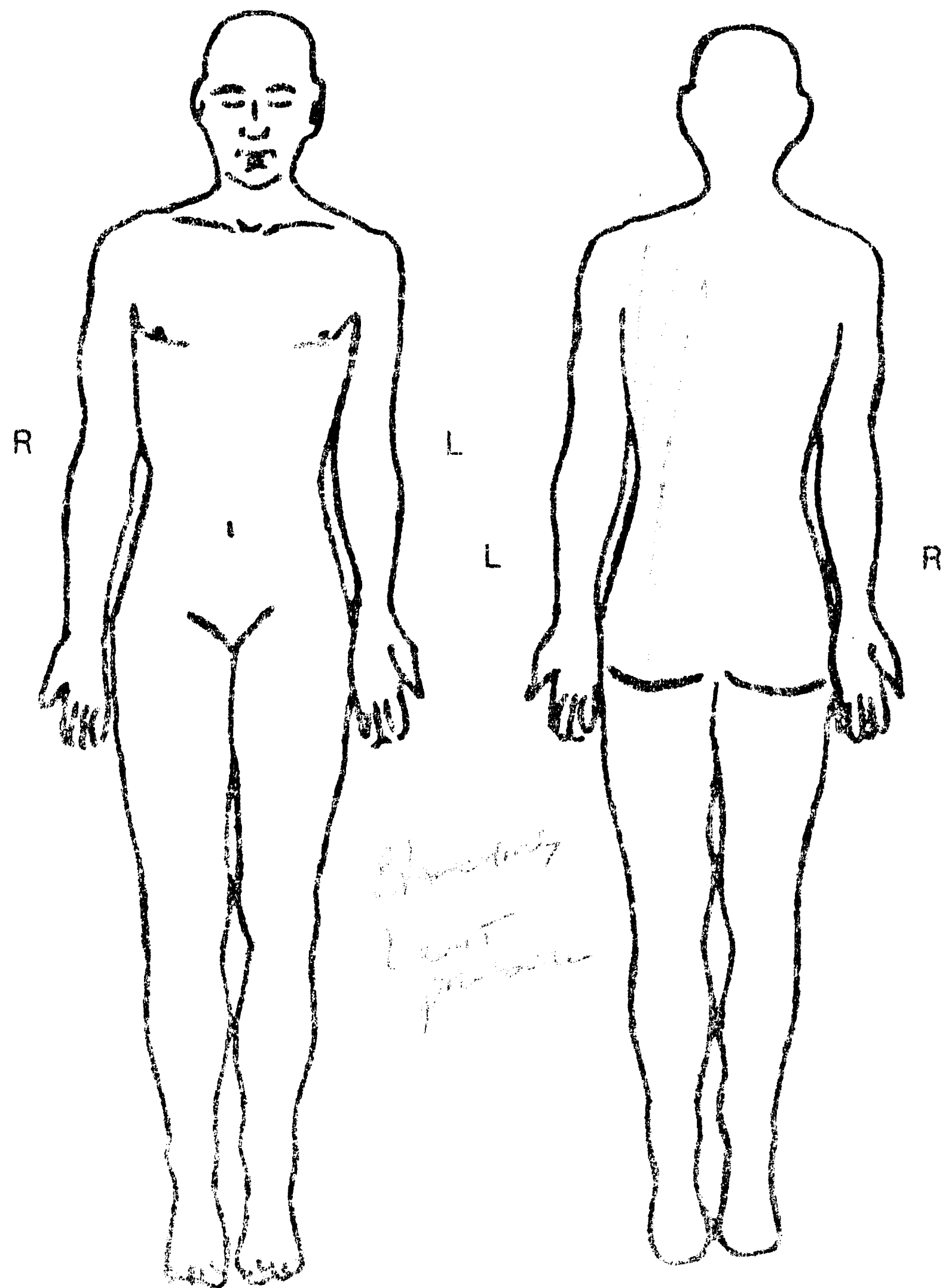
DESCRIPTION AS TO WHERE REMAINS FOUND AND CONTACT MATERIAL TO BODY:
Found on Couch

SCENE TEMPERATURE REGULATED? YES NO IF YES, THERMOSTAT SET AT _____ DEGREES F.

LIVOR MORTIS. TIME OBSERVED 1300 RIGOR MORTIS. TIME OBSERVED 1318

NECK FLEXION:
ANTERIOR 2
POSTERIOR 2
RT. LATERAL 2
LT. LATERAL 2

JAW 2 HIP 2
SHOULDER 2 KNEE 2
ELBOW 2 ANKLE 2
WRIST 2



Handwritten notes on the diagrams:
Shin
Left
pressure

SCALE
0 = ABSENT/NEGATIVE
1 +
2 +
3 +
4 = EXTREME DEGREE

USE SCALE TO DESCRIBE INTENSITY OF RIGOR MORTIS.

SHADE DIAGRAMS TO ILLUSTRATE THE LOCATION OF LIVOR MORTIS.

DESCRIBE INTENSITY OF COLORATION AND WHETHER LIVOR MORTIS IS PERMANENT OR BLANCHES UNDER PRESSURE.

[Signature]
CORONER'S INVESTIGATOR
REVIEWED BY

82

- Accident
- Homicide
- Suicide
- Questionable Accident/Homicide
- Questionable Accident/Suicide
- Questionable Suicide/Homicide
- Investigator Requests Rush

Kit #
C
3973

2008-09019
france, Russ

INFORMATION ABOUT DECEDENT/SHOOTING

Right Handed Left Handed Unknown Male Female

Occupation _____ Unknown

Activity Prior to Shooting outdoors

Have the decedent's hands been touched by anyone prior to taking the GSR sample? Yes No Unknown
If yes, by whom? Paramedics Family Police Hospital Personnel
 Other _____

Was the weapon found in the decedent's hand? Yes No Unknown - Moved prior arrival
If yes, which one? Right Left
If no, describe weapon's location in relationship to decedent on table in front of decedent

Shooting Occurred: Indoors Outdoors Unknown
Location of Body: Indoors Outdoors Automobile Hospital
Other _____

Number of Shots Fired: 2

Date unknown and Time _____ of Shooting

Date 12/25/8 and Time 1223 GSR samples were taken.

GSR evidence collected At Scene At FSC At Hospital
 Other _____ By: Hunter

Body transported to FSC via Coroner Contractor _____

FIREARM

Revolver Semi-automatic/automatic Rifle Shotgun
 Other _____

Make/Model Sig Sauer Caliber 9mm

AMMUNITION

Brand of Ammunition Win TP Caliber of Ammunition 9mm

Bullet Configuration: Round Nose Hollow Point Wad Cutter Pointed
Other _____

Bullet Surface: Jacketed Semi-jacketed Bare Lead Plated

Comments: 2 weapons - GSR Sauer but no shot

Investigator Hunter Date 12/25/8

Do not write below this line

RESULTS:

White: Medical file
Pink: Laboratory Copy
Yellow: Laboratory Copy



County of Los Angeles, Department of Coroner
Investigator's Narrative



Case Number: 2008-09019

Decedent: PARDO, BRUCE JEFFREY

Information Sources:

1. Detective J. Freund, LAPD Mission division 818- [REDACTED]

Investigation:

On 12/25/2008 at 0959 hours Detective Macciarella reported the apparent Suicide (gunshot wound) death of this adult male to Sylvia Hernandez. At 1115 hours Supervising Investigator Dietz assigned me to investigate this death and handle it as a homicide. I arrived at the scene at 1140 hours and departed the scene at 1438 hours.

Location:

INJURY/DEATH: residence/living room located at [REDACTED] Joseph CT Sylmar, 91342.

Informant/Witness Statements:

All information is preliminary and subject to change.

Detective Freund provided the following: the decedent had gone through a bitter divorce and had gone to a location in the City Of Covina dressed as Santa Claus and reportedly shot several people and ignited that location on fire. He was then discovered by his brother Brad Pardo [REDACTED] in Brad's residence when Brad returned home about 0310 hours on 12/25/2008. 911 was called with LAFD paramedics responding and pronouncing death at 0320 hours on 12/25/2008. One gun had been in the decedent's lap and the second in his hand unknown which. Both had been moved to the table by the decedent's brother at the direction of the 911 operator. An apparent suicide death gunshot wound to the head, no note. Covina Police Detectives are handling this investigation. Detective Stacy Franco 626- [REDACTED] and Detective Brian Kingwill 626- [REDACTED] 444 North Citrus Avenue Covina, 91723.

Two handguns, magazines and rounds were recovered at the scene and released to Covina PD Detectives.

1) Sig Sauer mod. P226 9mm semi-auto serial number U777822. This weapon had one round in the chamber with the hammer in the cocked position. There are 16 rounds in the magazine. Rounds are Luger +P 9mm jacketed hollow point.


2) Sig Sauer mod.P226 9mm semi-auto serial number U459976. This weapon had one round in the chamber and this magazine is empty. The round is a Luger +p 9mm jacketed hollow point.

Scene Description:

The scene is a single-family residence. The decedent is seated on the living room couch; there are two handguns on the table in front of him. A flashlight next to the decedent was dropped there by the decedent's brother. There is an apparent bullet hole in the ceiling above the decedent. There is damage to the wall behind the decedent. The residence is furnished and neat. When the decedent was moved there was a projectile recovered beneath him which was recovered by Covina PD Detectives. A spent casing had been recovered prior to my arrival on the couch by the decedent's buttocks and a second casing was located during my investigation under the decedent's right arm and collected by Covina Detectives.

Evidence:

Physical evidence was collected at the scene on 12/25/2008 including Hair kit, Nail kit, GSR kit #C3973 and physical evidence consisting of hair. Additional evidence including US Currency, keys, wig, gloves, paper and batteries were recovered from the decedent and released to Covina PD Detectives see evidence log for details. A special processing tag was initiated at the scene and transported with the decedent.



County of Los Angeles, Department of Coroner
Investigator's Narrative



Case Number: 2008-09019

Decedent: PARDO, BRUCE JEFFREY

Body Examination:

My initial field body examination revealed a supine adult male. He has short brown hair, blue eyes, natural teeth and is clean shaven. He is wearing a black thermal "T" shirt, black belt, black pants, green boxer style underpants, "girdle" with hard cup, black socks and black shoes. There are what appear to be remnants of a "Santa suit" around the left ankle and remnants of red material on his remaining clothing. There is a watch on the left wrist and ring on the left ring finger. The left front pants pocket contained a wallet, keys and fourteen cents. The right front pants pocket contained a pen, single key and quarter. The left rear pants pocket contained two white gloves and two batteries. The right rear pants pocket contained two papers and six batteries. There are burns, blistering and skin slippage on the hands and forearms. There is hair on the right hand stuck to the burns (recovered and booked into evidence). There is what appears to be masking tape around both forearms, with sections missing. This was left in place for examination by DME and later recovery. There is a scar on the left lower outer leg. There is an apparent entrance gunshot wound to the mouth with an apparent exit wound to the top of the head. Ambient temperature at 1306 hours is 55.4 degrees F and liver temperature at 1310 hours is 92.8 degrees F. Livor mortis is blanching with light pressure and consistent with found position. Rigor mortis is moderate (2). The decedent's tongue is clenched between his teeth. Additionally during the body examination a stack of money wrapped in clear plastic was found by the left calf with additional packages of money also wrapped in plastic in the "girdle" along with a wig and handcuff key with clear tape on it.

Identification:

The decedent is identified as Bruce Jeffrey Pardo by his California Drivers License [REDACTED]

Next of Kin Notification:

Who was notified by police and confirmed by Detective Freund.

Tissue Donation:

Next of kin not approached.

Autopsy Notification:

Detective Regan, Covina Police Department requests three hour examination notice.



RICHARD HANNA



LARRY DIETZ

12/25/2008

Date of Report

APPARENT MODE

SUICIDE

SPECIAL CIRCUMSTANCES

Gunshot Wound

1

LAST, FIRST MIDDLE PARDO, BRUCE JEFFREY #

ADDRESS LKA 4004 SUNSET AVENUE CITY MONTROSE STATE CA ZIP 91020

SEX RACE APPEARS DOB AGE HGT WGT EYES HAIR TEETH FACIAL HAIR ID VIEW CONDITION MALE CAUCASIAN 3/23/1963 45 in lbs BLUE BROWN ALL NATURAL TEETH CLEAN SHAVEN Yes FAIR

MARK TYPE MARK LOCATION MARK DESCRIPTION SCAR LEFT LEG

NOK ADDRESS CITY STATE ZIP

RELATIONSHIP PHONE NOTIFIED BY DATE TIME 12/25/2008

DL ID N9536618 STATE CA PENDING BY

ID METHOD CALIFORNIA DRIVER'S LICENSE LA # MAIN # CII # FBI # MILITARY # POB

IDENTIFIED BY NAME (PRINT) RICHARD HANNA RELATIONSHIP NONE PHONE (818) 364-3323 DATE TIME 12/25/2008

PLACE OF DEATH / PLACE FOUND PRIVATE RESIDENCE ADDRESS OR LOCATION 15835 JOSEPH CT CITY SYLMAR ZIP 91342

PLACE OF INJURY RESIDENCE/LIVING ROOM AT WORK No DATE TIME LOCATION OR ADDRESS 15835 JOSEPH CT, SYLMAR, CA ZIP 91342

DOD 12/25/2008 TIME 03:20 FOUND OR PRONOUNCED BY PARAMEDICS LAFD

OTHER AGENCY INV OFFICER LAPD MISSION HILLS - DETECTIVE FREUND PHONE (818) 838-9952 REPORT NO. NOTIFIED BY NO

TRANSPORTED BY TO LOS ANGELES FSC DATE TIME

Table with 4 columns: FINGERPRINTS?, CLOTHING, PA RPT, MORTUARY; MED. EV, INVEST. PHOTO #, SEAL TYPE, HOSP RPT; PHYS EV, EVIDENCE LOG, PROPERTY?, HOSP CHART; SUICIDE NOTE, GSR NO, RGPT. NO., PF NO.

SYNOPSIS DECEDENT IS A 45 YEAR-OLD MALE WITH NO REPORTED SOCIAL OR MEDICAL HISTORY. REPORTEDLY BITTER OVER A DIVORCE, POSSIBLY RESPONSIBLE FOR THE HOMICIDE DEATHS OF AT LEAST THREE OTHERS AND ARSON OF THE RESIDENCE. DECEDENT WAS DISCOVERED WITH AN APPARENT SELF-INFLICTED GUNSHOT WOUND BY HIS BROTHER IN HIS BROTHERS RESIDENCE. SUICIDE, NO NOTE.

RICHARD HANNA 459892 INVESTIGATOR DATE 12/25/2008 TIME 18:42 REVIEWED BY DATE TIME

FORM #3 NARRATIVE TO FOLLOW? ✓
