

Luis A. Sanchez, M.D.  
Chief Medical Examiner



Main: (713) 796-9292  
Fax: (713) 796-6844


Harris County Institute of Forensic Sciences

STATE OF TEXAS       §  
                                  §  
COUNTY OF HARRIS   §

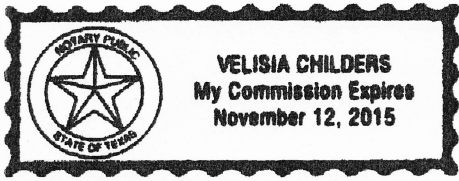
I, Luis A. Sanchez, M.D., Chief Medical Examiner of Harris County, do hereby certify that the attached autopsy report and toxicology report (where applicable) represent a true and correct copy of the Autopsy/External Examination findings on the body of

LaShandra Rena Charles, Case # Case 88-6085.

Witness my hand in Harris County, Texas, this 14th day of May, 2012.

  
\_\_\_\_\_  
Chief Medical Examiner  
Harris County, Texas

Subscribed and sworn to before me this 14th day of May, 2012.



  
\_\_\_\_\_  
Notary Public, Harris County, Texas



JOSEPH A. JACHIMCZYK, M.D., J.D.

FORENSIC PATHOLOGIST  
ATTORNEY AT LAW  
CHIEF MEDICAL EXAMINER



(713) 796-9292  
(713) 796-6815



OFFICE OF THE MEDICAL EXAMINER OF HARRIS COUNTY  
JOSEPH A. JACHIMCZYK FORENSIC CENTER  
1885 OLD SPANISH TRAIL  
HOUSTON, TEXAS 77054

AUTOPSY REPORT

Case 88 - 6085

September 27, 1988

PATHOLOGICAL DIAGNOSES ON THE BODY


OF


LaShandra Rena Charles  
2301 Hayes Road, #6214  
Houston, Texas

1. Stab wound of the neck.
2. Stab wound of the chest.

OPINION

It is our opinion that the decedent, LaShandra Rena Charles, came to her death as a result of stab wound of the neck, Homicide.

  
Joseph A. Jachimczyk, M.D., J.D.  
Chief Medical Examiner

  
Vladimir M. Parungao, M.D.  
Assistant Medical Examiner

## POSTMORTEM EXAMINATION ON THE BODY OF

LaShandra Rena Charles  
2301 Hayes Road, #6214  
Houston, Texas

**HISTORY:** This 15 year old black female was pronounced dead at 12:58 a.m., on September 27, 1988, at Ben Taub General Hospital. (See Companion Case 88 - 6084).

**AUTOPSY:** The autopsy was performed in the Joseph A. Jachimczyk Forensic Center of Harris County by Assistant Medical Examiner Vladimir M. Parungao, M.D., at the request of Chief Medical Examiner Joseph A. Jachimczyk, M.D., J.D., beginning at 10:00 a.m., on September 27, 1988.

**EXTERNAL APPEARANCE:** The body was that of a 15 year old black female, appearing older than the stated age, measuring 65 inches in length and weighing 127 pounds. The body was well developed and well nourished in appearance. There was total body rigidity and fixed postmortem lividity posteriorly. The head was normocephalic with a normal amount of kinky black hair which was beaded, measuring 12 inches in length. The eyes were covered with corneal caps. The ears and nose were unremarkable. The mouth contained natural teeth. The neck was symmetrical and stable. There was a stab wound in the left upper side at the left submandibular area. The thorax was symmetrical in shape and contour with unremarkable breasts bilaterally. There was a stab wound on the left side. The abdomen was flat. The external genitalia were those of a normal adult female with unremarkable pubic hair in normal distribution. There was no injury to the mucosa or submucosa of the vagina. The perineum was intact. The lower extremities showed no edema. The toenails were partially covered with red nail polish. The upper extremities showed recent needle punctures in the left and right cubital areas. The fingernails were covered with pink nail polish. The back was unremarkable. The cerebrospinal fluid was clear.

**INTERNAL EXAMINATION: Section:** The body was opened through the usual Y-shaped thoracoabdominal incision. There was a slight increase in subcutaneous fat and muscle tissue encountered upon dissection that measured 1-1/2 inches at the level of the umbilicus. There was a stab wound track involving the left 3rd intercostal space. There was also a stab wound track involving the left 4th intercostal space. After removal of the sternal plate, there were approximately 50 milliliters of blood tinged fluid in the left pleural cavity and none in the right. There were no adhesions observed. The pericardial sac was smooth and glistening and upon opening, there was no increase in fluid or adhesions. The abdominal

cavity contained no increase in fluid or adhesions. There was no organ displacement noted. The diaphragmatic domes were normally situated and the appendix was present in the right lower quadrant.

**HEART:** The heart weighed 275 grams. The epicardial surface was smooth and glistening. The epicardial fat was normal in amount and distribution. On section, the right ventricle averaged 3/16 inch in thickness and the left ventricle averaged 5/8 inch in thickness. The myocardium was beefy red in appearance. The endocardium, papillary muscles, chordae tendineae, the valves and their cusps, the foramen ovale, the coronary vessels and the aorta were all grossly unremarkable on section.

**LUNGS:** The right lung weighed 250 grams and the left lung weighed 200 grams. The pleurae were smooth and glistening. The fissures were well demarcated. On section, the parenchyma was grossly unremarkable. Examination of the tracheobronchial tree showed a small amount of mucoid secretions. Examination of the pulmonary vessels showed no evidence of thrombi or emboli.

**LIVER:** The liver weighed 950 grams. The capsule was smooth and glistening. On section, the parenchyma was orange-brown in appearance. The gallbladder contained 10 milliliters of bile and appeared grossly unremarkable as was the biliary tree.

**Pancreas:** The pancreas was normal in shape and configuration and on section, it was grossly unremarkable.

**Adrenals:** The adrenal glands were unremarkable, bilaterally.

**SPLEEN:** The spleen weighed 100 grams. The capsule was smooth and glistening. On section, the parenchyma was grossly unremarkable.

**GENITOURINARY TRACT:** The kidneys together weighed 210 grams. The capsules were thin, easily stripped, exposing a smooth surface. On section, the corticomedullary junctions were well demarcated. The calyces, pelves, ureters and urinary bladder were grossly unremarkable. The uterus with the attached cervix and both adnexa weighed 50 grams. On section, the cervix, endocervix, endometrium, myometrium, tubes and ovaries were grossly unremarkable.

**GASTROINTESTINAL TRACT:** The stomach was normal in shape and configuration. The serosal surfaces, muscularis layer and mucosa were grossly unremarkable. The lumen contained 50 milliliters of yellow-brown mucoid food particles. The duodenum and the rest of the small and large intestines including the appendix and esophagus were grossly unremarkable.

**BONES:** There were no fractures of the long bones.

NECK: There was soft tissue hemorrhage surrounding the stab wound track on the left side of the neck. There was transection of the left common carotid artery and the left jugular vein. The thyroid gland, larynx, vocal cords, epiglottis, hyoid bone and tongue were grossly unremarkable on section. The track ended in the soft tissues and muscles of the neck.

HEAD: The scalp was incised and reflected. There was no injury to the soft tissue and bone tissue of the skull. There was no subdural, epidural or subarachnoid hemorrhage. The meninges were smooth and glistening. The gyri and sulci were unremarkable. The cerebral hemispheres were symmetrical in shape and contour and the brain weighed 1250 grams. On section, the gray and white matter were well demarcated. The ventricular system, including the choroid plexus, was grossly unremarkable. The cerebellum and the midbrain were grossly unremarkable on section.

DESCRIPTION OF INJURIES: There was a stab wound in the left side of the neck at the left submandibular area located 2 inches to the left of midline and 8 inches below the top of the head. The wound measured 1-1/8 inches in length and gaped up to 1/8 inch in width. There was no blunt end. The stab wound track perforated the soft tissues and muscles of the neck, transected the left jugular vein and the left common carotid artery and the track ended in the soft tissues and muscles of the neck with an approximate depth of penetration of 3-1/2 inches. The direction of the stab wound was from front to back, slightly to the right and slightly upwards.

There was a stab wound in the left side of the chest located 1-1/2 inches to the left of midline, 4 inches below the suprasternal notch and 16 inches below the top of the head. The wound measured 1 inch in length and gaped up to 1/2 inch in width. There was no blunt end. The stab wound track perforated the soft tissues and muscles of the left side of the chest, entered the thoracic cavity through the left 3rd intercostal space and exited the thoracic cavity through the left 4th intercostal space without injuring any vital organs in the chest cavity. The track ended in the soft tissues and muscles of the back with an approximate depth of penetration of 4 inches. The direction of the stab wound was from front to back, slightly downwards and slightly to the left. There was no vital structure penetrated by this stab wound.

INVESTIGATOR'S REPORT

(X)AUTOPSY  
( )VIEW  
( )INQUEST ONLY

Investigator: James Ebdon

Case No. 88 - 6085

Decedent: LaShandra Rena Charles Race: B Sex: F Age: 15 D.O.B.: 11/1/1972

Home Address: 2301 Hayes Road, #6214, Houston, Texas Telephone: None

Date of Death: September 27, 1988 Time: 12:58 a.m. Found: No

Place of Death: Ben Taub General Hospital, Houston, Texas City(X)/County()/Pct()  
Emergency Room. Telephone:  
Zip Code: 77030

M.E. Notified: James Ebdon Date: September 27, 1988 Time: 3:15 a.m.

Place of Inquest: Via telephone. Date: September 27, 1988

Informant: Ms. Jenkins, Admitting Clerk Time: 3:15 a.m.

Next of Kin: Cynthia Charles (mother) Address: 2301 Hayes Road, #6214, Houston, Texas

Next of Kin Notified by: Sergeant Bloid Date: 9/27/1988 Time: 6:45 a.m.

Telephone: None

Personal Physician: Address:

Telephone:

Location, Position, and Surroundings of Body: The decedent was lying on her back on a hospital stretcher.

Clothing: The clothing consisted of a shirt.

Information: According to Ms. Jenkins, the decedent arrived at Ben Taub General Hospital via City of Houston Fire Department Ambulance #69 at 12:57 a.m., on September 27, 1988 and was pronounced dead at 12:58 a.m., on the same day by Doctor W. Bailey. The decedent and her cousin, Marcell Taylor, age 3, were both assaulted on a dirt pathway behind Fudrucker's Restaurant at 2475 South Kirkwood. Marcell Taylor (Companion Case 88-6084) and the decedent were both found on the pathway at 11:38 p.m., on September 26, 1988 and Marcell was already dead at the scene. They were found by Jaime Hunter. Houston Police Department Homicide Detective P. C. Bloid, Unit 1475, identified the decedent with the decedent's mother at 6:45 a.m., on September 27, 1988.

M.E. Photos: ( )Yes (X)No Police Agency: Houston Police Department  
Property: There was no property involved.

Case No.: 78815888

Funeral Home Transporting Decedent: Sheffield Funeral Home, Houston, Texas ( )Requested

Funeral Home Receiving Decedent: Johnson Funeral Home, Houston, Texas. (X)Dispatched